

CASE REPORT

A Case Report of left ventricle outflow tract (LVOT) Tumor in a 49 old day infant

Foroud Salehi¹, Arman Kocharian², Mohamad Ali Navabi³,
Mohammad Mehdi Hassanzadeh Taheri⁴✉

¹*Atherosclerosis and Coronary Artery Research Centre, Assistant Professor, Department of Cardiac Surgery, Birjand University Of Medical Science, Birjand, Iran;*

²*Professor of cardiologist pediatrician, MD, Dr Gharib Hospital, Tehran University of Medical Sciences, Tehran, Iran;*

³*Professor of heart surgeon, MD, Dr Gharib Hospital, Tehran University of Medical Sciences, Tehran, Iran;*

⁴*Associate professor of Anatomical Sciences, Anatomy Department, Birjand University of Medical Sciences, Birjand, Iran.*

Received: January 23, 2015

Revised: February 24, 2015

Accepted: March 7, 2015

Abstract

Rhabdomyomata are probably the most common tumors that occur very rarely during infancy. In this paper, we report the case of a 49-day-old infant who was diagnosed by echocardiography examination with left ventricle outflow tract (LVOT) obstruction caused by rhabdomyoma. The infant underwent surgical approach, and her mass was shaved. Finally, she was discharged from hospital in good general condition. Six-month follow-up after the operation did not show any obstruction.

Key Words: Infant; Tumor; Rhabdomyoma; Echocardiography

Introduction

Primary cardiac tumor in infancy and childhood are rare (1-4). Their incidence is estimated of 0.27 % among pediatric autopsies (4, 5) but 0.0017 has been reported among hospitalized for sick children in Toronto, Canada by Keith et al (6).

The commonest of these tumors, when present, probably are rhabdomyomata (5).

This disease to now have been diagnosed with echocardiographically (7-8). Because of occurrence of arrhythmia during evolution of rhabdomyoma, medical treatment will require, and the severe involvement infants usually die, due to obstruction of blood flow in the ventricular tract, therefore, operation may be undertaken to rescue them (9).

Tuberous sclerosis (CF) is often associated with

rhabdomyoma and must be sought (4, 9) and postnatal diagnosis of this tumor is often made when signs and symptoms of tuberous sclerosis complex (TSC) are identified (4, 10-11), or when there is a family history prompting cardiac assessment as part of clinical work-up (4).

In this presentation we report a rare case of cardiac

Cases

The case is a 49 old day infant who had natural delivery. She was a term baby that was born to healthy parents.

The infant referred from Milad Hospital in Tehran. The first physical examination was normal except for a grade 3/6 systolic murmur which was audible in her heart auscultation at the left upper



✉ Correspondence to:

Mohammad Mehdi Hassanzadeh Taheri, Associate professor of Anatomical Sciences, Anatomy Department, Birjand University of Medical Sciences, Birjand, Iran;
Telephone Number: 0985614433002
Email Address: mmhtahery35@yahoo.com

parasternal border and radiating to all area of the precordium.

The electrocardiogram and chest radiograph were normal. She had no cyanosis, respiratory distress and poorfeeding and hospitalized with good general condition.

Echocardiographic examination revealed a large lobulated hyperechogenic mass within the intraventricular septum extending into the left ventricular outflow tract (LVOT) and causing significant flow obstruction (figures 1& 2).

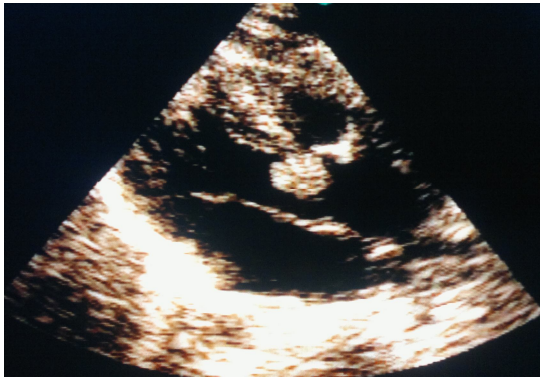

Figure 1: LVOT Tumor in LAX 2D echocardiography about (size=11x12mm)

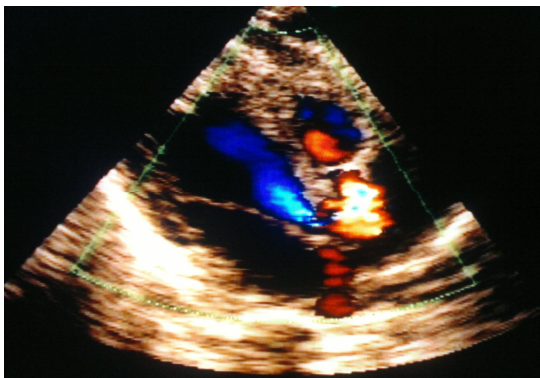

Figure 2: LVOT Tumor in LAX colerechocardiography (PG=55mmHg)

The functional diameter of the outflow tract was about 11×12 mm (fig 3) and the pressure gradient reached 55 mmHg.

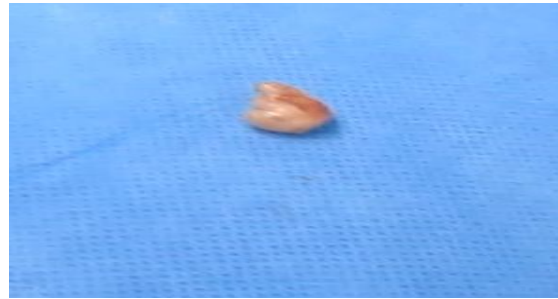


Figure 3: Resected tumor in size about 12*11mm. Macroscopy view of tumor (rhabdomyoma)

Despite of having severe LVOT, obstruction and left ventricular hypertrophy, the infant in this case did not show signs of hemodynamic compromise. After repeated cardiologic and surgical consultation, surgical approach were suggested.

Technique procedure: After preparing the infant for surgery, first mid sternotomy was done, by exposing the thymus, this organ transected and then pericardium opened on CPB, cool to 28 degree of centigrade. After Acc and CCCP, transverse aortotomy was performed. Thereafter, subaortic area was exposed and tumor shaved from septum (figure 3). RVOT opened to rule out iatrogenic LV, finally, defect aorta closed and RVOT pached and weaned from CPB. Heart characteristic as found via echocardiography are summarized in table no1.

Table 1: Cardiac characteristics finding through echocardiography

| Variable | Pre- treatment (Pre Op) | post-treatment (Post Op) |
|---------------|------------------------------------|--------------------------|
| Atrium | Normal | Normal |
| Ventricle | Normal | Normal |
| Great vessels | NRG | Normal |
| Valves | Mod/As PG=50mmhg Mean PG=28mmhg | No AI/NoAS |
| Septa | Intact | Intact |
| Lt of Ao Arch | LVOT mass size=11×12mm | Normal |
| NOPE | Normal | Normal |
| EF | 82% | 46% |

Discussion

Primary cardiac tumors are very rare in the infancy, and their incidence varies from 0.0017% in hospitalized pediatric patients to 0.27 % in autopsies (4, 6) and more than 90% of them are benign in nature (12). The most common variety of these tumors is the rhabdomyoma, and present in

over 60% of cases with tuberous sclerosis (12). The symptoms of cardiac rhabdomyoma include hemodynamic instability and life threatening arrhythmias usually requiring early surgical intervention (13). While, sometimes it may be completely asymptomatic and are incidentally discovered during an echocardiogram, or may cause cardiac dysfunctions requiring medical and/or surgical intervention (14).

Sanches et al have analyzed the patients with diagnosis of primary cardiac tumors between March 1977 and March 2007. The cases were 27 patients, and the age of initial diagnosis is more prevalent in the neonatal period (12). The most of the cases beginning with discovery of cardiac murmur in heart auscultation and echocardiography (12). The other diagnostic technique of choice, such as angio MRI (MRA) not being of much for diagnosis in children (12).

In 14 cases cardiomegaly were found on chest radiograph (12). Echocardiography revealed rhabdomyoma in 20 cases of them and the most defects were located in the left ventricle (12). There was no significant difference in gender distribution. In the 75% cases with rhabdomyoma presented or developed tuberous sclerosis. In 13 cases there was a spontaneous regression (12). The other investigations have shown that rhabdomyoma regress or disappear entirely without intervention (15, 16).

Verhaaren et al suggested that surgical intervention immediately after birth is indicated when cardiac outflow obstruction leads to significant hemodynamic compromise or life-threatening arrhythmias occur (16).

DeRosa et al reviewed the medical records of all cases of cardiac rhabdomyomas diagnosed prenatally or postnatally over an eight year period. All cases which studied were seven and had life-threatening conditions. Five cases were arrhythmic that controlled successfully by antiarrhythmic agents and two cases had blood flow obstruction with poor outcomes, that needed surgical indication. They concluded when prenatal diagnosis of rhabdomyoma is made, appropriate planning at delivery for the management of potential haemodynamic complications may prevent adverse neonatal outcomes (14).

Conclusions

Cardiac rhabdomyomas are the most frequent benign cardiac tumors. They are often

asymptomatic but can cause heart failure, arrhythmias and obstruction. In these cases they must be operated upon. The present case needed surgical intervention due to severe LVOT obstruction, that carried out and the patient rescue.

Acknowledgement

The authors of this article would appreciate Mrshabanian for revise and thank the sick infant's parents, in order to allowing this report.

References

- 1- Chan HS, Sonley MJ, Moës CA, Daneman A, Smith CR, Martin DJ. Primary and secondary tumors of childhood involving the heart, pericardium, and great vessels. A report of 75 cases and review of the literature. *Cancer*. 1985; 56(4): 825-36.
- 2- Watanabe T, Hojo Y, Kozaki T, Nagashima M, Ando M. Hypoplastic left heart syndrome with rhabdomyoma of the left ventricle. *Pediatr Cardiol*. 1991; 12(2): 121-2.
- 3- Maa HC, Wang KC. Rhabdomyoma of the left ventricle: A case report and review of literature. *Journal of Medical Sciences*. 1992; 13(3): 207-12.
- 4- Bader RS, Chitayat D, Kelly E, Ryan G, Smallhorn JF, Toi A, et al. Fetal Rhabdomyoma: prenatal diagnosis, clinical outcome, and incidence of associated tuberous sclerosis complex. *J Pediatr*. 2003; 143(5): 620-4.
- 5- Nadas AS, Ellison RC. Cardiac tumors in infancy. *Am J Cardiol*. 1968; 21(3): 363-6.
- 6- Keith JD, Rowe RD, Vlad P. Heart disease in infancy and childhood. 3rd ed. New York: Macmillan; 1980.
- 7- Allen HD, Blieden LC, Stone FM, Bessinger FB Jr, Lucas RV Jr. Echocardiographic demonstration of a right ventricular tumor in a neonate. *J Pediatr*. 1974; 84(6): 854-6.
- 8- Farooki ZQ, Henry JG, Arciniegas E, Green EW. Ultrasonic pattern of ventricular rhabdomyoma in two infants. *Am J Cardiol* 1974; 34(7): 842-4.
- 9- Milner S, Abramowitz JA, Levin SE. Rhabdomyoma of the heart in a newborn infant diagnosis by echocardiography. *Br Heart J*. 1980; 44(2): 224-7.
- 10- Cyr DR, Guntheroth WG, Nyberg DA, Smith JR, Nudelman SR, Ek M. Prenatal diagnosis of an intrapericardial teratoma: a cause for nonimmune hydrops. *J Ultrasound Med*. 1988; 7(2): 87-90.
- 11- Giacoia GP. Fetal rhabdomyoma: a prenatal echocardiographic marker of tuberous sclerosis. *Am J perinatol*. 1992; 9(2): 111-4.

- 12- Sánchez Andrés A, Insa Albert B, Carrasco Moreno JI, Cano Sánchez A, Moya Bonora A, Sáez Palacios JM. [Primary cardiac tumours in infancy]. *An Pediatr (Barc)*. 2008; 69(1): 15-22. [Spanish]
- 13- Etuwewe B, John C, Abdelaziz M. Asymptomatic cardiac rhabdomyoma in neonates: is surgery indicated? *Images Paediatr Cardiol*. 2009; 11(2): 1-8.
- 14-De Rosa G, De Carolis MP, Pardeo M, Bersani I, Tempera A, De Nisco A, et al. Neonatal emergencies associated with cardiac rhabdomyomas: an 8-year experience. *Fetal Diagn Ther*. 2011; 29(2): 169-77.
- 15- Segal I, Nir A. Rhabdomyoma causing severe left ventricular outflow obstruction in a newborn: A management dilemma. *Pediatr Cardiol* 2010; 31(2): 303-5.
- 16-Verhaaren HA, Vanakker O, De Wolf D, Suys B, François K, Matthys D. Left ventricular outflow obstruction in rhabdomyoma of infancy: meta-analysis of the literature. *J Pediatr*. 2003; 143(2): 258-63.