

Survival after left ventricular free wall rupture due to acute myocardial infarction

Mahmood Hosseinzadeh-Maleki⁽¹⁾, Niloufar Valizadeh⁽²⁾, Niloofar Rafatpanah⁽²⁾,
Seyed Ali Moezi⁽³⁾

Case Report

Abstract

BACKGROUND: Left ventricular free wall rupture is a frequent catastrophic complication of acute myocardial infarction (AMI) and occurs in 1-3% of patients with acute myocardial infarction; it is the third most common cause of death caused by acute myocardial infarction, too.

CASE REPORT: We describe acute left ventricular free wall rupture due to acute myocardial infarction in a 60-year-old man. He was survived after urgent surgical intervention.

CONCLUSION: The long-term survivors of free wall rupture repair have not been extensively reported; early diagnosis is very critical and immediate surgical repair is the treatment of choice.

Keywords: Myocardial Infarction, Free Wall Rupture, Left Ventricle

Date of submission: 4 May 2014, *Date of acceptance:* 14 May 2015

Introduction

Left ventricular free wall rupture (LVFWR) is a frequent catastrophic complication, and the third most common cause of death after acute myocardial infarction (AMI). This most severe mechanical complication of the AMI occurs in 1-3% of patients and often remains undiagnosed.^{1,2}

Case Report

We describe 60-year-old man with acute left ventricular free wall rupture due to AMI. He was admitted in emergency department with severe retrosternal chest pain, dyspnea, and sweating. A presumed diagnosis of anterior wall AMI with ST segment elevation was made. Treatment with streptokinase was started. Retrosternal chest pain was relieved, but the ST segment elevations did not resolve. The patient was transferred to a cardiac care unit.

The coronary angiography demonstrated a three-vessel disease with proximal significant stenosis of the left anterior descending (LAD) and right coronary (RCA) arteries and totally occluded left circumflex artery (LCX) filling via collaterals (Figure 1).

The patient was discharged after 7 days and candidate for elective coronary artery bypass graft (CABG). Six hours after discharge, he was brought

back to emergency department in a state of hemodynamic collapse. His blood pressure was 60/45 mmHg; his heart rate was 130 beats/minute; and an electrocardiogram showed sinus tachycardia. Signs of systemic hypoperfusion and cardiogenic shock were noted, and intra-aortic balloon pump (IABP) support was started immediately. Further electrocardiography revealed sinus tachycardia, low-voltage QRS complexes with diffuse ST segment elevation, and no electrical changes. Echocardiography revealed a moderate pericardial effusion and manifestations of early cardiac tamponade [right atrium (RA) and right ventricle (RV) diastolic collapse] but no signs of myocardial tear, mitral regurgitation, or ventricular septal defect.

The patient was transported to the operating room, and midsternotomy was done. Later, 300 ml of blood and clot was drained from the pericardium, and cardiopulmonary bypass (CPB) was established. Rupture of anterolateral wall of LV was repaired via Gore-Tex and Dacron patch, and CABG was done (Figures 2-4).

The patient recovered quickly and after 12 days, he was discharged from the hospital.

At the 18-month follow-up, the patient was taking statins, diuretics, β -blockers, angiotensin-

1- Assistant Professor, Atherosclerosis and Coronary Artery Research Center AND Department of Cardiovascular Surgery, School of Medicine, Birjand University of Medical Sciences, Birjand, Iran

2- Student of Medicine, Atherosclerosis and Coronary Artery Research Center AND School of Medicine, Birjand University of Medical Sciences, Birjand, Iran

3- Assistant Professor, Atherosclerosis and Coronary Artery Research Center AND Department of Cardiology, School of Medicine, Birjand University of Medical Science, Birjand, Iran

Correspondence to: Seyed Ali Moezi, Email: seidali@yahoo.com

converting enzyme (ACE) inhibitors, and warfarin. Follow-up echocardiography revealed a left ventricular ejection fraction of 35% to 40%, mild enlargement of the left ventricle, and mild mitral valve regurgitation.

Discussion

In 1647, William Harvey reported the first clinical case of post-infarction left ventricular wall rupture.³ Left ventricular free wall usually occurs between 3 to 6 days

following AMI, and the survival is associated with emergency operation.⁴ Previous studies report that the anterior wall is more often susceptible to rupture, and the more recent studies indicate that the rupture is more common on the lateral or posterior wall.² In a review of cases, the segmental distribution of free-wall rupture location was posterior wall (43%), lateral wall (28%), and then apical wall (24%) followed by other segments at equal frequency.⁵ In our patient, the anterolateral wall was involved.

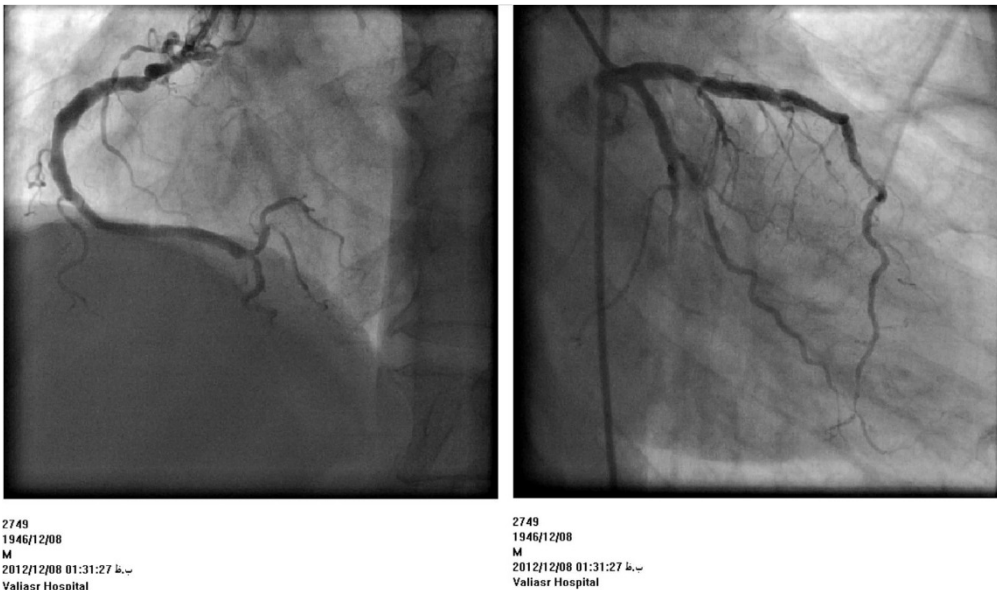


Figure 1. The coronary angiography views

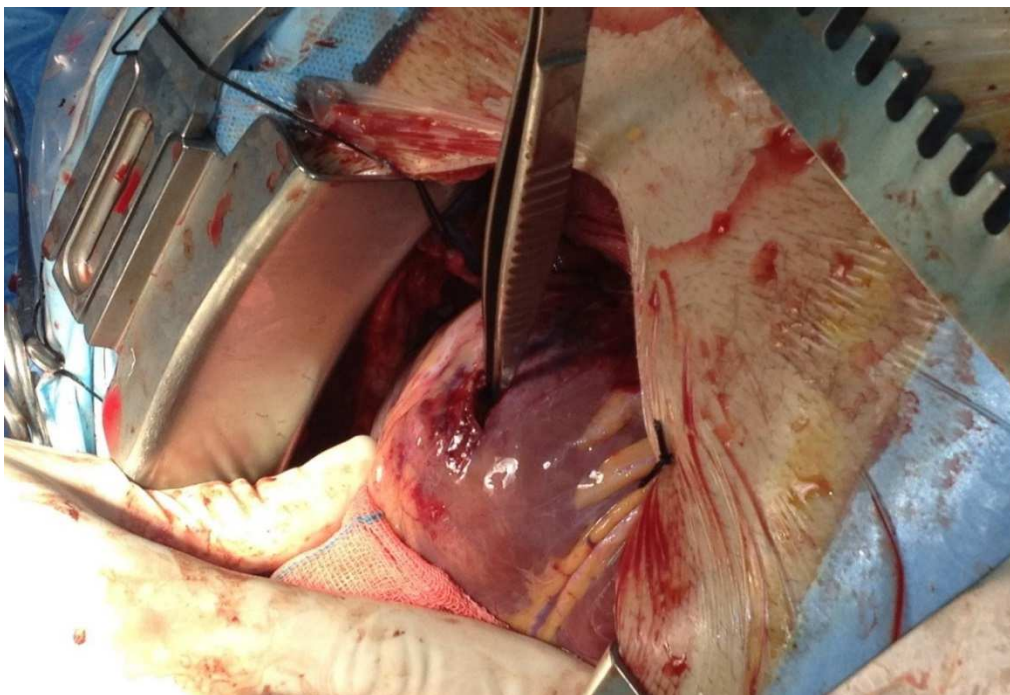


Figure 2. Left ventricular free wall rupture after acute myocardial infarction (AMI)

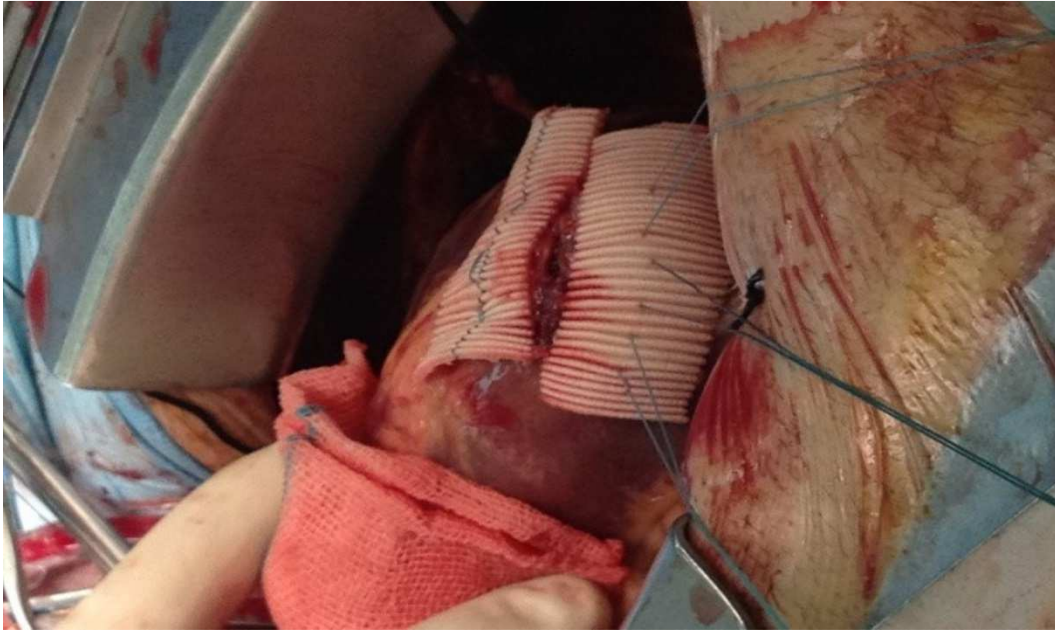

Figure 3. Repair of left ventricular rupture with Dacron patch

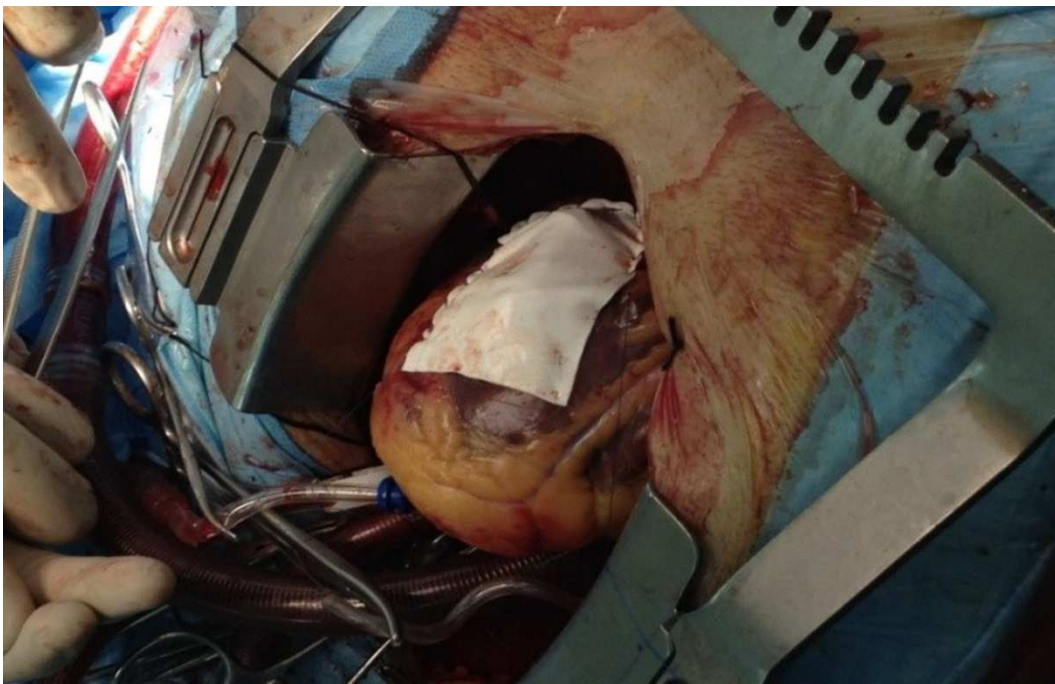

Figure 4. Reinforcement of left ventricular rupture after repair with Gore-Tex patch

Rupture of the ventricular free wall and cardiogenic shock are the major causes of death following AMI, contributing to 66% of deaths due to first AMI.⁶

The evolution of the events in acute free wall rupture rarely provides the adequate time to treat the patient surgically.⁷ Patients usually die within a few minutes. This most fatal complication of the AMI often remains undiagnosed and constitutes a necropsy finding.⁷ Surgical treatment of myocardial

free wall rupture has been achieved with different degrees of success.⁸

However, when there is strong suspicion of cardiac rupture, biological glue can be administered intrapericardially following pericardiocentesis, ensuring valuable time until the patient is led to the operating room. The goals of surgery include avoiding cardiac tamponade and performing closure of the ventricular deficit.

In our case, since there was no delay in surgical

treatment, we used an IABP counter-pulsation. Placement of IABP was very useful in the patient who brought in the emergency room with evidence of cardiogenic shock following AMI.⁹

Localized pericardial effusion is the most frequent echocardiographic finding in the case of left ventricular free wall rupture. Thus, echocardiography can aid in early diagnosis of cardiac rupture. In our case study, echocardiography and IABP played a prominent role for management of AMI complication.

Comment

This case demonstrates that left ventricular free wall rupture is not always fatal. Early diagnosis and institution of intra-aortic balloon pump support in such patients can allow successful bridging to definitive emergency surgical therapy.

Acknowledgments

None

Conflict of Interests

Authors have no conflict of interests.

References

1. Roa-Castro V, Molina-Bello E, Valenzuela-Suarez H, Rotberg-Jagode T, Espinola-Zavaleta N. Survival after Left Ventricular Free Wall Rupture in an Elderly Woman with Acute Myocardial Infarction Treated Only Medically. Hindawi Publishing Corporation 2012; 2012: 1-6.
2. Exadaktylos NI, Kranidis AI, Argyriou MO, Charitos CG, Andrikopoulos GK. Left Ventricular Free Wall Rupture During Acute Myocardial Infarction. Early Diagnosis and Treatment. Hellenic J Cardiol 2002; 43: 246-52.
3. Willius FA, Jan Dry TJ. A History of the Heart and the Circulation. Philadelphia, PA: W.B. Saunders Company; 1948.
4. Bashour T, Kabbani SS, Ellertson DG, Crew J, Hanna ES. Surgical salvage of heart rupture: report of two cases and review of the literature. Ann Thorac Surg 1983; 36(2): 209-13.
5. Frances C, Romero A, Grady D. Left ventricular pseudoaneurysm. J Am Coll Cardiol 1998; 32(3): 557-61.
6. Batts KP, Ackermann DM, Edwards WD. Postinfarction rupture of the left ventricular free wall: clinicopathologic correlates in 100 consecutive autopsy cases. Hum Pathol 1990; 21(5): 530-5.
7. David TE. Surgery for postinfarction rupture of the free wall of the ventricle. In: David T, Editor. Mechanical Complications of Myocardial Infarction. Austin, TX: R.G. Landes Company; 1993. p. 142.
8. Pappas PJ, Cernaianu AC, Baldino WA, Cilley JH, DelRossi AJ. Ventricular free-wall rupture after myocardial infarction; Treatment and outcome. Chest 1991; 99(4): 892-5.
9. Mottahedi B, Hosseinzadeh Maleki M, Javan H, Zirak N, Ghorbani E, Shakeri MT. Mortality Predictors For Intra Aortic Balloon Pump Support After Cardiac Surgery. Iranian Journal of Cardiac Surgery 2012; 4(2-3): 6-8.

How to cite this article: Hosseinzadeh-Maleki M, Valizadeh N, Rafatpanah N. **Survival after left ventricular free wall rupture due to acute myocardial infarction.** ARYA Atheroscler 2015; 11(5): 310-3.